

The “Turtleneck” Pulley Plasty for Finger Flexor Tendon Repair

Jean-Noel Goubier, MD, PhD, Thibault Lafosse, MD, and Frédéric Teboul, MD, MS

Abstract: Injuries to the flexor tendons are frequent. Even when correctly treated, they can cause a loss of mobility of the digits secondary to postoperative adhesions. Further, conflicts between the tendon suture and the pulleys can limit the range of motion of the tendon and the flexion of the fingers. We propose a new pulley plasty that permits immediate retraining and avoids conflict with the tendon suture. Ten patients underwent surgery for a tendon injury in zone II, with no lesions of the associated pedicles. The tendons were repaired by a 4-strand stitch technique associated with a continuous peritendinous suture. Pulley plasty was systematically performed on A2, A4, or both. Eight patients recovered a satisfactory range of motion with a finger to palm distance of <1 cm, and 2 others with a distance of <2 cm. Two tenolyses were performed, for which no secondary reconstruction of the pulleys was necessary. This plasty technique is simple to carry out, reliable, and reproducible. Because it facilitates tendon repair and reinforces the existing pulleys, it permits immediate retraining and controlled active mobilization.

Key Words: pulley, tendon, flexor tendon, plasty

(*Tech Hand Surg* 2014;18: 8–9)

HISTORICAL BACKGROUND

Injuries to the flexor tendons are frequent and can have significant adverse consequences for function, even if correctly repaired. Indeed, adhesions linked to the scarring of the tendon and the flexor tendon sheaths can limit the range of motion of the tendon.^{1–3} In addition, conflicts between the tendon suture after repair and the pulleys can limit the mobility of the digit. Plasty techniques have been proposed to address this issue, to allow the conservation of the indispensable pulleys, notably A2 and A4, while providing sufficient space to permit a normal range of motion.^{4–8} However, in certain patients, the sheath and thickness of the pulleys is extremely fine, and a plasty can reduce their resistance to tendon stress. To address this problem, we propose a pulley plasty technique, which allows the avoidance of tendon conflicts and the reinforcement of the remaining pulleys.

TECHNIQUE

The patient was placed in a supine position with their arms on a table. A pneumatic tourniquet cuff was placed at the base of the limb and inflated. After cleaning and trimming the wound and verifying the neurovascular pedicles, the sheath of the tendon was washed. Thereafter, the proximal extremities of the flexor tendons were recovered, directly in the sheath or with the help of a counter incision in the palm if the tendons had retracted. Once the tendons had been recovered, they were held with an

intra-dermic needle. Thereafter, to permit easier suturing of the tendon and to reinforce the A2 and/or A4 pulleys, the A2 and/or A4 pulleys were sectioned along their radial and ulnar osseous insertion, from 1 to 3 mm (up to 50% of the length of the pulley; Fig. 1A). Then, the sectioned portion was reflected upon itself like a “turtleneck” (Fig. 1B) and sutured to itself with a fine resorbable 5/0 thread (Fig. 1C). The flexor tendon was then sutured with a 4-strand technique (4-strand cross-locked cruciate), associated with a peripheral epitendinous continuous suture (interlocking horizontal mattress suture; Fig. 2). When the flexor tendon suture was complete, the intra-dermic needle was removed. The finger was lightly stretched and flexed to verify the absence of conflict with the A2 and A4 pulleys. The wound was then closed by interrupted stitches. The forearm and the hand were immobilized in a brachioradial splint for a period of 6 weeks to protect the suture.

Patients underwent daily physical therapy by passive and controlled active mobilization, beginning the second day after operation.

INDICATIONS/CONTRAINDICATIONS

This pulley plasty can be performed for all flexor tendon wounds. Indeed, whatever the pulley size, a part of it can be incised and returned on itself.

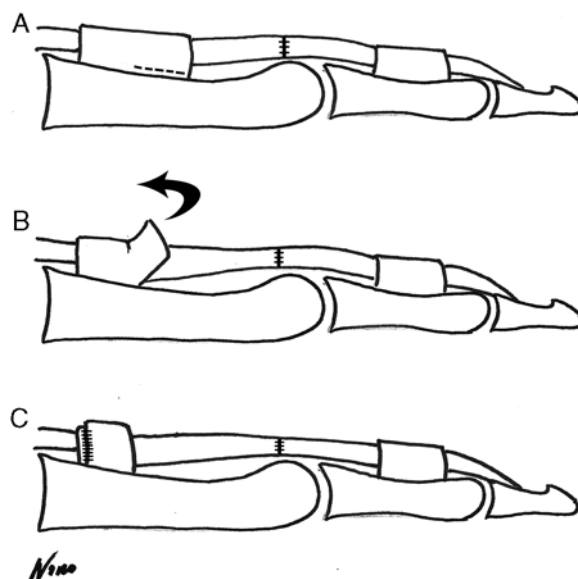


FIGURE 1. Schematic explaining “turtleneck” pulley plasty. A, The pulley is sectioned at the level of its osseous insertion on the radial and ulnar side, along 1 to 3 mm (up to 50% of its length). B, The released portion is returned on itself like a “turtleneck” to permit easier suturing of the flexor tendon and avoid conflicts between the suture and the pulley. C, The reflected portion of the pulley is sutured with resorbable 5/0 thread on the remaining pulley, to reinforce it.

From the International Center of Hand Surgery, Paris, France.

Conflicts of Interest and Source of Funding: The authors report no conflicts of interest and no source of funding.

Address correspondence and reprint requests to Jean-Noel Goubier, MD, PhD, International Center of Hand Surgery, 92 Bd de Courcelles, Paris 75017, France. E-mail: jngoubier@gmail.com.

Copyright © 2013 by Lippincott Williams & Wilkins

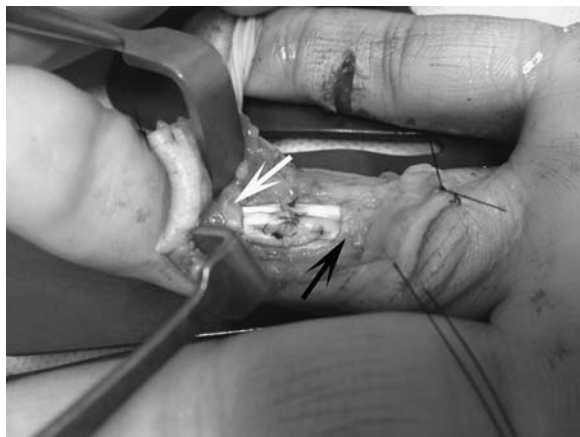

FIGURE 2. Preoperative image showing a pulley plasty for A2 (black arrow) and A4 (white arrow).

No contraindications for this technique exist. However, a part of the pulley must obviously still be inserted on the phalanx. The technique is not possible to perform in a tenolysis when the pulley has disappeared. In this case, reconstruction of the pulley is necessary, aided by classic techniques.⁹

COMPLICATIONS

We have found no direct complications associated with this technique. However, it is necessary to be prudent while suturing the pulley to itself, so as to not suture the underlying flexor tendon at the same time and to ensure that the tendon slides perfectly after the pulley plasty.

RESULTS

We have reviewed 10 patients who presented a section of the flexor tendons in zone II. The repair of the flexor tendons was performed by one 4-strand cross-locked cruciate, as well as a “turtleneck” pulley plasty involving A2, A4, or both. After 6 months the finger extension had completely recovered. The finger to palm distance was <10 mm in 8 patients and >20 mm in 2 patients. These 2 patients required a tenolysis. The tenolysis was performed without difficulty, considering the presence of good quality pulleys, not requiring their reconstruction and permitting a recovery of the finger to palm distance to <10 mm. No patients presented a secondary pulley rupture.

DISCUSSION

Wounds to the flexor tendons are frequent but can have significant functional consequences. Indeed, because of adhesions on the sheath during scarring, the range of motion of the tendon can be limited.^{1,2} Further, there can be conflicts between the tendon suture and the adjacent pulleys. These pulleys must be conserved to permit a normal range of motion of the flexor tendons and to ensure a satisfactory grip force, which occasionally necessitates a reconstruction when they are damaged. Nevertheless, their presence can render the tendon

suture difficult under otherwise good conditions. To balance these 2 objectives, numerous pulley plasties have been described, from simple partial resection to the complete, unilateral disinsertion of the pulley.^{4,8,10}

However, certain plasties can weaken the pulley. Indeed, in the case of isolated partial resection of the pulley, the stresses linked to the forces of flexion of the flexor tendons are applied on a weaker surface, which can cause distension of the pulley.^{8,10} Further, in plasties that entirely release the pulley along its full length, placing a ring is indispensable during retraining, to avoid a secondary rupture.⁴

The shortening of the pulley in our technique (linked to the eversion of one part of the pulley), as in techniques of partial resection of the pulley, allows suturing of the flexor tendon under good conditions¹¹ and avoids conflict between the suture and the pulleys. Further, the reinforcement of the remaining pulley allows retraining by controlled active mobilization, without the use of a protective ring as with other techniques.⁴

Finally, this plasty can be practiced on all annular pulleys, notably A2 and A4, those most important. This technique is simple and therefore reproducible.

REFERENCES

1. Doyle J, Blythe WF. *The Finger Flexor Tendon Sheath and Pulleys: Anatomy and Reconstruction*. AAOS Symposium on Tendon Surgery in the Hand. St. Louis: CV Mosby; 1975.
2. Doyle JR, Blythe WF. Anatomy of the flexor tendon sheath and pulleys of the thumb. *J Hand Surg Am*. 1977;2:149–151.
3. Tang JB, Xie RG, Cao Y, et al. A2 pulley incision or one slip of the superficialis improves flexor tendon repairs. *Clin Orthop Relat Res*. 2007;456:121–127.
4. Bakhach J, Sentucq-Rigal J, Mouton P, et al. The Omega “Omega” pulley plasty. A new technique to increase the diameter of the annular flexor digital pulleys. *Ann Chir Plast Esthet*. 2005;50:705–714.
5. Dona E, Walsh WR. Flexor tendon pulley V-Y plasty: an alternative to pulley venting or resection. *J Hand Surg Am*. 2006;31:133–137.
6. Mehrotra S. Trigger finger: functional pulley release by ‘N’-plasty. *J Plast Reconstr Aesthet Surg*. 2010;63:e114–e115.
7. Pabari A, Branford OA, Iyer S. Trigger finger: functional pulley release by ‘N’-plasty. *J Plast Reconstr Aesthet Surg*. 2010;63:e803–e804.
8. Paillard PJ, Amadio PC, Zhao C, et al. Pulley plasty versus resection of one slip of the flexor digitorum superficialis after repair of both flexor tendons in zone II: a biomechanical study. *J Bone Joint Surg Am*. 2002;84-A:2039–2045.
9. Clark TA, Skeete K, Amadio PC. Flexor tendon pulley reconstruction. *J Hand Surg Am*. 2010;35:1685–1689.
10. Bunata RE. Primary pulley enlargement in zone 2 by incision and repair with an extensor retinaculum graft. *J Hand Surg Am*. 2010;35:785–790.
11. Moriya T, Thoreson AR, Zhao C, et al. The effects of oblique or transverse partial excision of the A2 pulley on gliding resistance during cyclic motion following zone II flexor digitorum profundus repair in a cadaveric model. *J Hand Surg Am*. 2012;37:1634–1638.