



ELSEVIER

Contents lists available at ScienceDirect

Injury

journal homepage: [www.elsevier.com/locate/injury](http://www.elsevier.com/locate/injury)

## Endoscopic brachial plexus neurolysis in the management of infraclavicular nerve injuries due to glenohumeral dislocation

Malo Le Hanneur<sup>a,b,1,\*</sup>, Manon Colas<sup>a,b,1</sup>, Julien Serane-Fresnel<sup>a,b</sup>, Laurent Lafosse<sup>b</sup>, Amaury Grandjean<sup>c,d</sup>, Jonathan Silvera<sup>e,f</sup>, Thibault Lafosse<sup>a,b</sup>

<sup>a</sup>Alps Surgery Institute – Hand, Upper Limb, Brachial Plexus and Microsurgery Unit (PBMA), Clinique Générale d'Annecy, 4 chemin de la Tour la Reine, 74000 Annecy, France

<sup>b</sup>Department of Orthopedics and Traumatology – Service of Hand, Upper Limb and Peripheral Nerve Surgery, Georges Pompidou European Hospital (HEGP), Assistance Publique Hôpitaux de Paris – Paris Descartes University, 20 rue Leblanc, 75015 Paris, France

<sup>c</sup>Centre Epau Main de Provence (CEMP), Hôpital Privé Provence, 235 allée Nicolas de Stael, 13080 Aix-en-Provence, France

<sup>d</sup>Clinique Axiom, 42 avenue du Maréchal de Lattre de Tassigny, 13090 Aix-en-Provence, France

<sup>e</sup>Imagerie Médicale Paris Centre (IMPC) Bachaumont, 6 rue Bachaumont, 75002 Paris, France

<sup>f</sup>Clinique Blomet, 136 rue Blomet, 75015 Paris, France

### ARTICLE INFO

#### Article history:

Accepted 2 August 2020

Available online xxx

#### Keywords:

Brachial plexus  
Infraclavicular  
Neurolysis  
Release  
Endoscopy  
Arthroscopy  
Shoulder  
Glenohumeral  
Joint  
Dislocation

### ABSTRACT

**Introduction:** Infraclavicular brachial plexus (BP) injury secondary to glenohumeral joint (GHJ) dislocation is a rather common complication, which may be accountable for long-lasting deficits. The purpose of this study was to assess the potential benefits of BP neurolysis in such presentation, using an endoscopic approach.

**Materials and methods:** All patients who underwent endoscopic BP neurolysis in the setting of infraclavicular BP palsy due to GHJ dislocation were included. Preoperative physical examination was conducted to classify the observed motor and sensitive deficits into nerves and/or cord lesions. Six weeks after the trauma, examination was repeated and endoscopic BP neurolysis was elected if no significant improvements were observed. If nerve ruptures and/or severe damages were identified during surgery, nerve reconstructions were conducted within a month; in other cases, follow-up examinations were conducted at 6 weeks, 3 and 6 months to assess the course of postoperative recovery.

**Results:** Eleven patients were included, including 6 men and 5 women, with a mean age of  $43 \pm 23$  years (16;73). Six patients had at least one cord involved, four patients had isolated axillary nerve palsy, and one patient had a complete BP palsy. In 7 patients with cord lesions and/or isolated axillary nerve palsy, at least grade-3 strength, according to the British Medical Research Council grading system, was noted in all affected muscles within 6 weeks following the neurolysis; after 3 months of follow-up, grade-4 strength was observed in all muscles, and all but patients but one had fully recovered within 6 months. In 3 patients with isolated axillary nerve palsy, complete nerve ruptures ( $n=2$ ) and severe damages ( $n=1$ ) were identified under scopic magnification; secondary nerve transfers were conducted to reanimate the axillary nerve, and all patients fully recovered within a year. In one patient with complete BP palsy, improvements started after 6 months of follow-up, and full recovery was yielded after 2 years. No intra- and/or postoperative complications were noted.

**Conclusions:** At the cost of minimal additional morbidity, endoscopic BP neurolysis appears to be a safe and reliable procedure to shorten recovery delays in most patients presenting with BP palsy due to GHJ dislocation.

© 2020 Elsevier Ltd. All rights reserved.

\* Corresponding author at: Department of Orthopedics and Traumatology – Service of Hand, Upper Limb and Peripheral Nerve Surgery, Georges Pompidou European Hospital (HEGP), Assistance Publique Hôpitaux de Paris – Paris Descartes University, 20 rue Leblanc, 75015 Paris, France.

E-mail address: [malo.lehanneur@gmail.com](mailto:malo.lehanneur@gmail.com) (M. Le Hanneur).

<sup>1</sup> These authors equally contributed in the conception of this manuscript.

<https://doi.org/10.1016/j.injury.2020.08.005>

0020-1383/© 2020 Elsevier Ltd. All rights reserved.

## Introduction

With an incidence rate varying from 11.6 to 80.5 cases per 100,000 persons per year, anterior dislocation of the glenohumeral joint (GHJ) is a rather common injury, predominantly affecting young and active patients [1,2]. In 5.4 to 55% of cases, concomitant palsy of the brachial plexus (BP) or one of its terminal branches may occur [3]. Considering that such complications severely worsen patients' functional prognosis and that the risk of permanent nerve damages depends on the delay of reduction, initial physical examination of patients suffering from GHJ dislocation should primarily focus on neurological lesions [4,5]. Due to their anatomic location, all infraclavicular BP terminal branches may be affected, including from most to least frequently involved the axillary, ulnar, median, radial and musculocutaneous nerves [6,7]; if such BP palsies are incomplete in the majority of cases, several terminal branches are most commonly involved, corresponding to cord lesions (i.e., anteromedial, anterolateral and posterior cords) [8–12]. With the combination of traction and compression forces, grade-I to grade-V lesions may be encountered, even if neurotmesis lesions appear to be rather uncommon [10,11,13–15].

Since spontaneous recovery is observed in most cases, numerous authors tend to consider these lesions as benign and advocate for non-operative managements [3,11,16,17]. However, very long periods of time can be observed between the initial trauma and full recovery, with permanent distal deficits requiring palliative surgeries in the most severe cases [16]. Furthermore, if nerve reconstruction is not indicated to obtain satisfactory outcomes in most palsies resulting from axonotmesis lesions, neurotmesis lesions should be repaired as soon as possible to improve chances of recovery [10], and early differentiation between these two types of lesions cannot be made without surgical exploration in some cases [15].

With the recent advances in shoulder arthroscopic surgery, standardized procedures have been described to perform extensive dissections outside of the glenohumeral joint and expose the entire infraclavicular BP [18–20]. Using such techniques, comprehensive releases of all cords and terminal branches can be made, allowing the identification and treatment of potential nerve compression sites, perineural soft-tissue adhesions as well as intraneural lesions, at the cost of minimal surgical morbidity [19–21].

On the grounds of previously published literature [3,15,18,19,22–24], we established a standardized algorithm to manage infraclavicular BP palsies secondary to GHJ dislocation, based on early endoscopic BP neurolysis. The purpose of this study was to assess the outcomes that such strategy could provide in patients showing no significant signs of spontaneous recovery within 6 weeks following the initial trauma.

## Materials and methods

### Population criteria

All patients who were referred to our institution from November 2017 to August 2019 in the setting of post-traumatic BP palsy due to GHJ dislocation were included. Patients who demonstrated significant clinical signs of spontaneous recovery within 6 weeks following the initial trauma were excluded from the study.

### Preoperative management

A comprehensive initial physical examination was conducted in order to assess the muscular strengths of each muscle of the affected upper limb and compare those to the contralateral side, using the British Medical Research Council (BMRC) grading system. Monofilament testing was conducted upon both upper limbs as

**Table 1**  
Definitions of the lesions.

Neurological lesions*	Motor deficits	Sensitive deficits
Musculocutaneous nerve palsy	Biceps brachii / Brachialis	Palmar and dorsal sides of the forearm lateral aspect
Median nerve palsy	PT / FCR / PL / FPL / FDP2-3 / FDS2-3-4-5 / PQ / OP / APB / Lombrical1-2	Palmar side of the hand lateral aspect / thumb / second finger / third finger / fourth finger lateral aspect
Ulnar nerve palsy	FCU / FDP4-5 / Hypothenar Muscles / IO / Lumbrical3-4 / AP	Dorsal and palmar sides of the hand medial aspect / fourth finger medial aspect / fifth finger
Axillary nerve palsy	Deltoid / Teres minor	Shoulder lateral aspect
Radial nerve palsy	Triceps brachii / BR / ECR L / ECRB / Supinator / ECU / EPL / EPB / APL / EDC / EIP / EDM	Dorsal side of the arm / forearm / hand lateral aspect
Anterolateral cord palsy	Muscle(s) innervated by the musculocutaneous nerve AND PT / FCR	Musculocutaneous nerve territory AND Median nerve territory
Anteromedial cord palsy	Muscle(s) innervated by the median nerve (apart from PT and FCR) AND Muscle(s) innervated by the ulnar nerve	Ulnar nerve territory AND Palmar and ulnar sides of the forearm medial aspect
Posterior cord palsy	Muscle(s) innervated by the axillary nerve AND Muscle(s) innervated by the radial nerve	Axillary nerve territory AND Radial nerve territory
Complete brachial plexus palsy	Combination of motor and/or sensitive deficits from all cords	

PT: pronator teres; FCR: flexor carpi radialis; PL: palmaris longus; FPL: flexor pollicis longus; FDP: flexor digitorum profundus; FDS: flexor digitorum superficialis; PQ: pronator quadratus; OP: opponens pollicis; APB: abductor pollicis brevis; FCU: flexor carpi ulnaris; IO: interossei; AP: adductor pollicis; BR: brachioradialis; ECR L: extensor carpi radialis longus; ECRB: extensor carpi radialis brevis; ECU: extensor carpi ulnaris; EPL: extensor pollicis longus; EPB: extensor pollicis brevis; APL: abductor pollicis longus; EDC: extensor digitorum communis; EIP: extensor indicis proprius; EDM: extensor digiti minimi.

\* Nerve lesions were defined by ascertainment of at least one motor and/or sensitive deficit in the nerve territory during clinical examinations; cord lesions were defined by the combination of motor and/or sensitive deficits from two different nerve territories.

well, grading the cutaneous sensitivity of the different nerve territories from 0 (i.e., anesthesia – no sensitivity) to 2 (i.e., normal sensitivity – symmetric to the unaffected side), with grade-1 sensitivity corresponding to hypoesthesia (i.e., protection sensitivity). At the end of examination, motor and sensitive deficits were synthesized and classified in nerve and/or cord lesions (Table 1). In order to maintain passive ranges of motion and stimulate para-

lyzed muscles, a rehabilitation program was established at the end of consultation, associating standard and neuropathic pain medications, self-rehabilitation postural maneuvers and physiotherapy sessions.

Six weeks after the trauma, physical examination was repeated in order to decide whether or not the patient would undergo arthroscopic BP neurolysis. In cases of satisfactory clinical recovery, defined as grade-4 or higher muscular strength and grade-1 or higher sensitivity in all the initially affected nerve territories, non-operative management was elected; rehabilitation was resumed and clinical follow-up was conducted every 3 months until full recovery was yielded. In patients demonstrating insufficient clinical recovery (i.e.,  $\leq$  grade-3 strength and/or grade-0 sensitivity), an electrophysiological (EDX) study of the affected upper limb and a BP magnetic resonance imaging (MRI) scan were conducted to confirm the palsy extent that had been clinically assessed and look for prognostic information (e.g., denervation and/or reinnervation potentials on the EDX study; muscular denervation changes and/or intraneural edema on the MRI scan). The MRI scan included the ipsilateral shoulder to assess potential associated osteoarticular and/or musculotendinous lesions. Several criteria were taken into account to select either a conservative or an operative approach, including the clinical extent and severity of the deficit, the course of clinical recovery, as well as the EDX and MRI data (Fig. 1). When patients were referred lately to our institution (i.e., more than 6 weeks after the dislocation), assessment of the course of clinical recovery was based on data retrieved from medical reports of the previous institution(s).

#### *Surgical technique*

With the patient set up in a beach chair position and axial traction applied upon the upper limb, surgery was performed under general anesthesia without loco-regional anesthesia. All patients were operated on by the senior author, using the technique previously described by Lafosse et al. [20].

Briefly, a posterior portal was first created in the shoulder soft point to enter the scope in the GH joint, allowing the assessment and management of articular and/or tendinous lesions. An instrumental anterolateral portal was then created in the rotator interval, which was developed using an electrocautery probe. Dissection was resumed outside of the joint by creating successive additional portals, medial to the shoulder, under scopic visualization. The retropectoral and subclavicular spaces were developed to expose the infraclavicular BP, using the coracoid process, the conjoint tendon and the upper border of the pectoralis minor as landmarks. The axillary artery was used to identify the different cords (i.e., anterolateral, anteromedial and posterior). The subclavius muscle and the pectoralis minor tendon were then transected to expose the infraclavicular BP terminal branches, including the musculocutaneous, median, ulnar, radial and axillary nerves. The latter were released from any soft-tissue adhesions until they reached the retrocoracoid space, so that their aspect and continuity could be assessed under scopic magnification.

#### *Postoperative care*

The patient was discharged the day after surgery once active bleeding and/or significant blood loss were ruled out by systematic postoperative blood count. The upper limb was placed in a sling for 2 days to limit the risk of hematoma; after that, immobilization was removed and the patient was told to use the operated arm as much as possible for all daily living activities. As soon as postoperative pain and swelling decreased, usually within the week following surgery, rehabilitation was resumed using the same protocol as preoperatively.

Two weeks after surgery, patients were seen in clinics to check on surgical wounds and rehabilitation observance. If neurotmesis lesions were identified during endoscopic exploration, secondary nerve transfers were subsequently scheduled at this time. Otherwise, physical examinations, as described above, were conducted at 6 weeks, 3 months and 6 months after surgery in order to assess postoperative clinical recovery.

#### *Data collection*

Before any data collection and/or analysis, the study was registered in the database register of the National Committee of Computer Science and Liberties (i.e., Commission Nationale de l'Informatique et des Libertés - CNIL; No 2217505 version 0). A retrospective chart review was then conducted in accordance with the ethical standards of the Declaration of Helsinki of 1964 and the Methodology of Reference MR-003 [25].

An independent observer retrieved all pre- and postoperative data, as well as intraoperative findings. In all cases, patients benefited from GHJ reduction at other centers and were referred to our institution secondarily. Subsequently, the characteristics of the dislocation (e.g., date and type of GHJ dislocation, side of injury, delay between GHJ dislocation and reduction, need of general anesthesia for GHJ reduction) were retrieved from the medical reports of these previous centers. For clarity purpose, all motor deficits observed in a nerve and/or cord territory during pre- and postoperative examinations were summarized to a single BMRC grade per territory; since surgical indication was based on the most severe deficit, the lowest grade was used. Similar synthesis was conducted for sensitive deficits, using the lowest sensitivity grade observed in the affected upper limb to summarize the sensitivity of the entire limb.

## **Results**

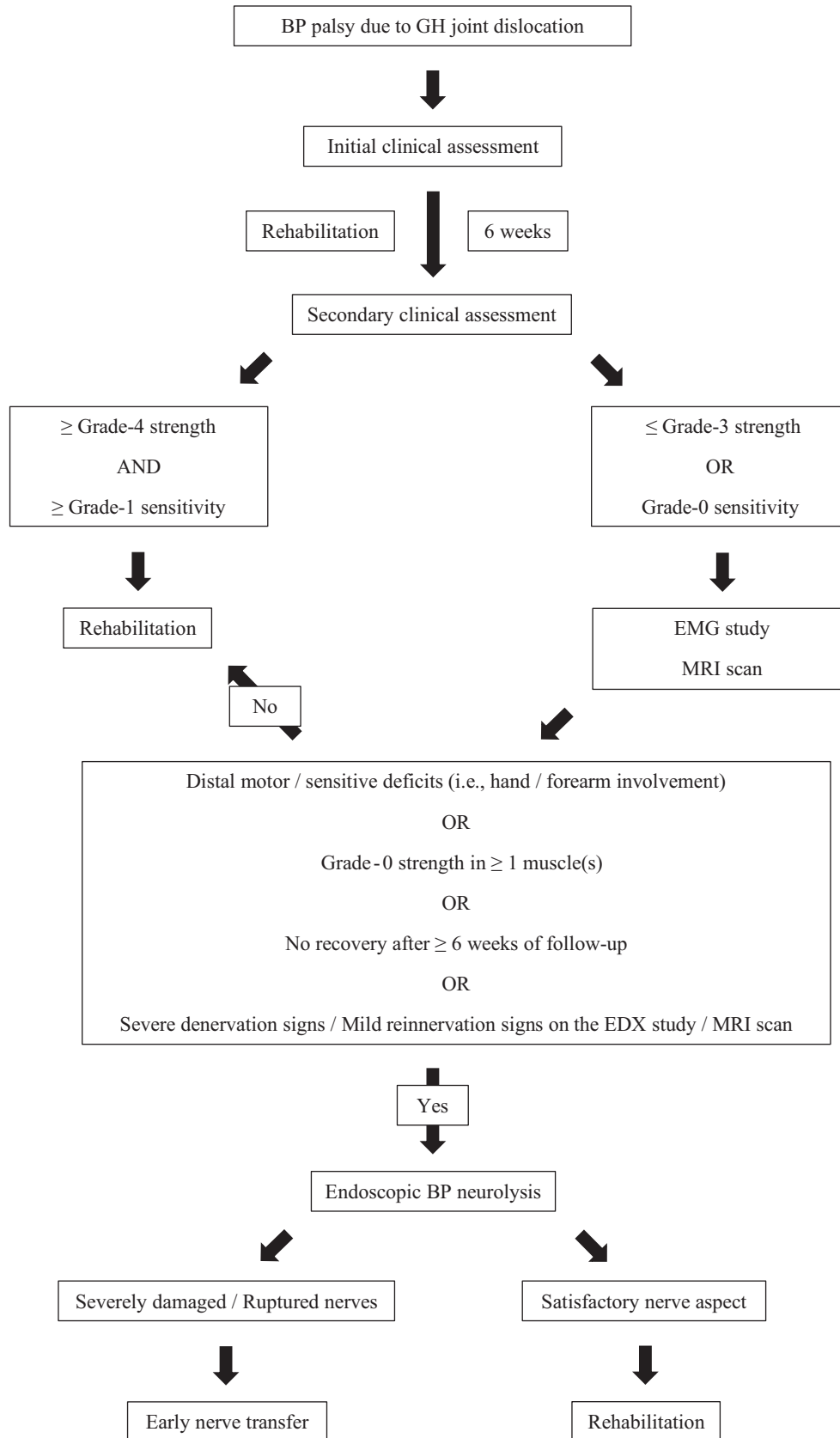
#### *Series characteristics*

Twenty patients met our inclusion criteria. Among them, nine patients completely recovered within 6 weeks following GHJ dislocation and were subsequently excluded from the study; no patient was lost during follow-up. Regarding the 11 remaining patients, 6 were male and 5 were female, with a mean age of  $43 \pm 23$  years (16;73) at the time of trauma.

All patients had suffered from a first episode of anteroinferior GHJ dislocation, which involved the right shoulder in 7 cases. Before undergoing endoscopic BP exploration, 6 patients had incomplete palsies involving at least one cord, 4 had an isolated palsy of the axillary nerve and the last patient had a complete palsy of the infraclavicular BP. With 6 patients who were referred lately to our institution, a mean preoperative delay of  $111 \pm 77$  days (46;301) was observed between the initial trauma and the release surgery; details of patients' preoperative characteristics are presented in Table 2.

#### *Surgical findings*

During GHJ exploration, degenerative posterosuperior rotator cuff tears were identified in 2 patients; since none of them complained of shoulder functional limitations before the dislocation, no attempt of repair was undertaken. In one patient, a traumatic avulsion fracture of the greater tuberosity was identified (i.e., equivalent of shoulder terrible triad); however, due to late referral (i.e., more than 9 months), cuff retraction up to the glenoid neck level as well as spinati muscles fatty infiltration were identified on the preoperative MRI scan; subsequently, no attempt of repair was undertaken.



**Fig. 1.** Therapeutic algorithm regarding patients suffering from infraclavicular BP paralysis secondary to GH joint dislocation. BP: brachial plexus; GH: glenohumeral; EDX: electrophysiologic; MRI: magnetic resonance imaging.

**Table 2**  
Series characteristics.

Patients (No)	11
Age (years)	43 ± 23 (16;73)
Sex ratio (M/F, No)	6 / 5
Dominance (R/L, No)	8 / 3
Glenohumeral dislocations	
Dominant side (No)	9
Anteroinferior direction (No)	11
Delay between trauma and reduction (hours)	6.5 ± 7.5 (1;24)
Reduction under general anesthesia (No)	4
Concomitant lesions (No)	
Greater tuberosity fracture	6
Bony-Bankart lesion	1
Rotator cuff tear	3
Infraclavicular brachial plexus palsies (No)	
Delay between trauma and first consultation (days)	75 ± 77 (6;272)
Delay between trauma and brachial plexus neurolysis (days)	111 ± 77 (46; 301)
Types of palsy (No)	
Isolated axillary nerve palsy	4
Cord palsy	6
Posterior cord & ulnar nerve	1
Anteromedial cord & posterior cord	4
Anteromedial cord & anterolateral cord & radial nerve	1
Complete palsy	1

No: number of cases/patients in absolute values; Male: male; F: female; R: right; L: left.

\*Data are presented as mean ± standard deviation (interval), unless otherwise stated.

**Table 3**

Postoperative findings following arthroscopic brachial plexus neurolysis in the setting of brachial plexus palsy due to glenohumeral dislocation.

Groups	Findings	Number of cases
A	Early postoperative improvements	7
B	Early indication for nerve transfer	3
C	Absence of benefit	1

In all cases, severe adhesions were found outside of the anterior and medial aspects of the glenohumeral joint, sheathing the infraclavicular BP and/or its terminal branches. Precautious and progressive dissection allowed exposing all cords and nerves in all patients. In 2 patients presenting with an isolated palsy of the axillary nerve, neurotmesis lesions (i.e., Sunderland grade-V lesions) were identified; in a third patient with similar clinical presentation on initial examination, the axillary nerve appeared to be very damaged under scopic magnification and felt “empty” when palpated with the smooth end of an arthroscopic switching stick. No intraoperative or postoperative complications were reported.

### Clinical outcomes

Based on the observed outcomes following endoscopic BP neurolysis, three groups of patients could be distinguished, as outlined in Table 3.

In 7 patients (i.e., group A), clinical improvements were observed in all the affected nerves and/or cords within 6 weeks following the neurolysis, with at least grade-3 strength noted in all muscles (Table 4). These patients demonstrated at least grade-4 strength in all muscles after 3 months of follow-up, and all but one yielded full recovery, both motor and sensitive, within 6 months after the neurolysis. Due to late referral, the patient with persistent deficits at the 6-months follow-up visit had undergone arthroscopic BP neurolysis almost 10 months after GHJ dislocation (Patient 7 – Table 4). If shoulder and elbow functions completely recovered, lesser grip strength was noted in the affected hand than in the contralateral hand on Jamar testing; since she did not complain about any functional limitations, no additional procedures were performed towards the hand.

In 3 patients (i.e., group B), the endoscopic BP exploration led to schedule early double nerve transfers to reanimate the axillary nerve anterior branch and the teres minor motor branch, using triceps brachii motor branches through an axillary approach [26]. Regarding the two patients with neurotmesis lesions, nerve transfers were performed within a month following the neurolysis procedure. The last case was performed in a patient who had been referred lately to our institution (i.e., 102 days), suffering from complete palsies of both the deltoid and teres minor muscles with no signs of recovery on initial clinical examination; as previously stated, severe axillary nerve damages were noted under scopic magnification. After 3 months of follow-up, considering postoperative clinical improvements not satisfactory (i.e., grade-1 deltoid strength and grade-0 teres minor strength), a secondary double nerve transfer was elected. Intraoperatively, stimulation of the axillary nerve triggered a weak response in the deltoid and teres minor muscles; subsequently, end-to-side transfers were performed to both motor branches (i.e., supercharge transfers). Full recovery (i.e., grade-5 deltoid and teres minor strengths) was noted within 12 months following nerve transfers in all three patients.

In 1 patient presenting with a complete BP palsy on initial examination (i.e., group C), no postoperative improvements were observed within the first 6 months of follow-up, despite the absence of nerve ruptures and/or severe damages noticed during endoscopic exploration. After 6 months, recovery started at the shoulder (i.e., grade-2 deltoid strength) and progressed distally towards the hand over 18 months. After 2 years of follow-up, at least grade-4 strength was observed in all muscles, with the exception of hand intrinsic muscles. Tendon transfers were subsequently performed, including Zancolli lassos to restore long fingers metacarpophalangeal joint flexion, extensor pollicis brevis to first palmar interosseous to reinforce the thumb-index pinch, and an extensor indicis proprius opponensplasty.

### Secondary procedures

In addition to the nerve and tendon transfers previously exposed, 2 patients with irreparable posterosuperior rotator cuff tears underwent reverse shoulder arthroplasty, including one patient who had benefited from end-to-end nerve transfers of triceps motor branches to the axillary nerve, with grade-4 deltoid strength after 11 months of follow-up. Arthroplasties were

**Table 4**  
Characteristics of patient presenting early improvements following endoscopic brachial plexus neurolysis.

Patients	Initial presentation*	Preoperative delay (days)	Follow-up findings*			Additional procedures
			6 weeks	3 months	6 months	
1	Posterior cord - 2/5 Anteromedial cord - 2/5 Sensitivity - 1/2	50	Posterior cord - 4/5 Anteromedial cord - 4/5 Sensitivity - 2/2	Posterior cord - 5/5 Anteromedial cord - 5/5 Sensitivity - 2/2	Posterior cord - 5/5 Anteromedial cord - 5/5 Sensitivity - 2/2	-
2	Posterior cord - 0/5 Anteromedial cord - 2/5 Sensitivity - 0/2	75	Posterior cord - 3/5 Anteromedial cord - 4/5 Sensitivity - 2/2	Posterior cord - 4/5 Anteromedial cord - 4/5 Sensitivity - 2/2	Posterior cord - 5/5 Anteromedial cord - 5/5 Sensitivity - 2/2	-
3	Anterolateral cord - 0/5 Anteromedial cord - 0/5 Radial nerve - 2/5 Sensitivity - 1/2	82	Anterolateral cord - 5/5 Anteromedial cord - 3/5 Radial nerve - 5/5 Sensitivity - 1/2	Anterolateral cord - 5/5 Anteromedial cord - 4/5 Radial nerve - 5/5 Sensitivity - 1/2	Anterolateral cord - 5/5 Anteromedial cord - 5/5 Radial nerve - 5/5 Sensitivity - 2/2	-
4	Posterior cord - 0/5 Ulnar nerve - 2/5 Sensitivity - 1/2	47	Posterior cord - 4/5 Ulnar nerve - 4/5 Sensitivity - 1/2	Posterior cord - 5/5 Ulnar nerve - 5/5 Sensitivity - 2/2	Posterior cord - 5/5 Ulnar nerve - 5/5 Sensitivity - 2/2	-
5	Posterior cord - 0/5 Anteromedial cord - 0/5 Sensitivity - 0/2	48	Posterior cord - 3/5 Anteromedial cord - 3/5 Sensitivity - 2/2	Posterior cord - 5/5 Anteromedial cord - 4/5 Sensitivity - 2/2	Posterior cord - 5/5 Anteromedial cord - 5/5 Sensitivity - 2/2	-
6	Axillary nerve - 0/5 Sensitivity - 1/2	140	Axillary nerve - 3/5 Sensitivity - 1/2	Axillary nerve - 4/5 Sensitivity - 2/2	Axillary nerve - 5/5 Sensitivity - 2/2	-
7	Posterior cord - 1/5 Anteromedial cord - 0/5 Sensitivity - 0/2	302	Posterior cord - 4/5 Anteromedial cord - 3/5 Sensitivity - 1/2	Posterior cord - 4/5 Anteromedial cord - 4/5 Sensitivity - 2/2	Posterior cord - 5/5 Anteromedial cord - 4/5 Sensitivity - 2/2	Reverse shoulder arthroplasty

\* Strength was graded using the British Medical Research Council grading system; for clarity purpose, the grade reported in front of the nerve/cord corresponds to the grade of the most affected muscle innervated by this nerve/cord. Sensitivity was graded 0 (i.e., anesthesia), 1 (i.e., hypoesthesia) or 2 (i.e., normal sensitivity); for clarity purpose, the reported grade corresponds to the worst sensitivity that was observed in the cutaneous territory of the affected nerve/cord.

performed after at least one year following the last procedure (i.e., endoscopic neurolysis or nerve transfer) for septic considerations and to favor deltoid reinforcement. Satisfactory outcomes were observed in both cases, with at least 120° and 30° of active shoulder flexion and external rotation, respectively.

## Discussion

In this study, we reported our strategy regarding the management of traumatic infraclavicular BP palsies following GHJ dislocation, based on early endoscopic BP neurolysis. If such procedure did not provide significant benefit to the natural course of recovery in one case, early and fast postoperative improvements were observed in 7 patients, yielding satisfactory function within 6 weeks after the surgery in all cases and complete recovery within 6 months in all patients but one. In addition, we were able to schedule early nerve transfers in patients with neurotmesis and/or severe axonotmesis lesions. However, several essential points still need to be clarified, starting with the very basis of such strategy.

### Indication of early BP exploration

If the different characteristics of infraclavicular BP palsies following GHJ dislocations are widely described, few authors proposed an explicit algorithm regarding the indication of surgical exploration [3]. When considering the literature referring to other post-traumatic nerve injuries, several authors advocate for early neurolysis as the first step of surgical management [22]. As an example, Keighley and colleagues, based on a complete recovery rate of 100% after 6 to 8 months of follow-up, recommended to perform systematic radial nerve releases in patients presenting radial nerve palsies secondary to middle and distal humerus fractures [23]. Similarly, in their series of 122 patients suffering from iatrogenic peripheral nerve lesions, Rasulic et al. observed 85.4% of satisfactory recovery in 48 patients who underwent nerve exploration within the first 6 months, against 67.6% in the 74 patients who were operated on after this delay [24].

If such attitude is not commonly adopted in cases of infraclavicular BP palsy due to GHJ dislocation, it is primarily related to

the fact that, provided that a sufficiently long period of follow-up is respected, spontaneous recovery is more often observed in this particular type of post-traumatic palsies than in others [9,27–29]. Except in cases of high-energy trauma and/or associated fractures, the risk of nerve rupture is low due to the blunt aspect of the humeral head as well as the anatomical characteristics of the infraclavicular BP (e.g., distant from the exit of the spinal cord, no anatomical fixation point) [15,30,31]. Subsequently, very satisfactory complete recovery rates have been reported by different authors, varying from 75 to 100% [9,16,32]. However, the delays of recovery displayed in these studies could be rather significant, varying from a few weeks in patients with simple neurapraxia lesions to 23 months in patients with axonotmesis lesions [16,32]. Furthermore, other authors noted that nerve reconstruction was required in only 13 to 18% of patients presenting such palsies, with preoperative delays most commonly superior than 3 months [11,33,34]. In the present series, much shorter delays were observed, with grade-3 strength observed in all affected muscles within 6 weeks following the release in 7 patients with axonotmesis lesions. Moreover, in the 3 patients who required nerve reconstructions, the latter were performed within the first 3 months following the dislocation in all cases.

### Timing of surgery

Timing for surgical exploration remains controversial in post-traumatic nerve palsies, since the physician has to find the right compromise between allowing spontaneous nerve regeneration and preventing irreversible motor end plate losses with subsequent muscular atrophy [35]. Accordingly, numerous studies recommended delaying surgical management at least 3 to 6 months after the initial trauma [33,36,37], while others authors advised to avoid waiting more than 6 to 9 months [38,39]. For example, Battiston and colleagues considered that the optimal interval between the trauma and operative intervention is 5.4 months [40]. However, early surgical exploration, undertaken within 3 months after the trauma, seems to be supported by a growing number of authors [3,10,40,41].

In this series, we respected an interval of 6 weeks to avoid operating on patients with neurapraxia and/or mild axonotmesis lesions who would have spontaneously recovered satisfactory function within a short period of time. Meanwhile, this also prevents from long-lasting follow-up periods whose effects might be substantial in terms of social impact, which can be dramatic in young and active patients, but also in terms of motor end plate degeneration, which starts very early after the trauma [42]. Such short time frame for surgical exploration has already been proposed in cases of isolated axillary palsies without recovery within 2 months following the trauma, in order to look for nerve ruptures [11].

#### *Underlying pathophysiology*

Based on the work of Brown, early surgical nerve release has been assumed to avoid the occurrence of scar tissues surrounding otherwise healthy nerve fascicles, leading to further aggravation of clinical symptoms [43]. Following GHJ dislocations, in addition to the compression and traction axonal injuries directly related to the humeral head impact onto the infraclavicular BP, perineural adhesion formations develop from the post-traumatic hematoma, aggravating local BP compression and degrading its gliding properties [10]. By excising the scar tissues, neurolysis recreates a more favorable environment for the nerves. In this series, clinical improvements were noticed in all patients from group A almost immediately after they woke up from surgery. Subjective improvements were major, with complete vanishing of the compression sensations at the proximal aspect of the arm and tremendous decrease of paresthesia that patients described preoperatively. Moreover, very early sensitive and/or motor improvements were noticed as well in most cases, either immediately after surgery or at the 2-weeks follow-up consultation. We believe that this group of patients most probably suffered from “refractory” neurapraxia with mild axonotmesis lesions, which presentation was substantially worsened by the perineural fibrosis that was removed during surgery.

Although patients with neurotmesis lesions are rather rare [7,11,17,33], such procedure is particularly beneficial to them since there is no chance to obtain any functional improvements without nerve reconstruction [15]. Early ascertainment of nerve discontinuity thus allows performing nerve transfers in a very short time frame. Similarly, in cases of preserved nerve continuity, visualization of severe nerve damages during endoscopic exploration as well as the absence of early improvements despite a comprehensive nerve release are strong arguments for the physician to perform an early nerve reconstruction. The benefits of such early operative interventions include prevention of clinically significant end plate losses, alleviation of neuropathic pain and limitation of the risk of neuroma formation [3]. In patients from group B, with all nerve reconstructions performed within 3 months following the initial trauma, full recovery was yielded within the first year following the nerve transfer.

#### *Limitations of the technique*

In this series, one patient did not show any improvement following the neurolysis (i.e., group C). Functional improvements started 6 months after the trauma and a progressive recovery was observed over 18 months of follow-up, in a proximal-to-distal fashion. We believe that this patient suffered from moderate axonotmesis lesions (i.e., Sunderland type-III lesions), which are, in our opinion, one of the primary limitations to this technique, especially when no obvious signs of damage are visible on the nerve superficial aspect. Indeed, since axonal regeneration is mandatory to allow satisfactory muscle activity, releasing perineural scar tissues is not sufficient in this particular type of lesions to obtain

early functional improvements [16]. Furthermore, the superficial nerve sheath is most often preserved in such lesions, precluding the endoscopic identification of intraneural lesions [35].

Another limitation of this technique is its inherent technicality and the subsequent long learning curve that is required to perform it safely [19–21]. Since one of the main arguments supporting this procedure is its minimal morbidity, it is of primary importance that the surgeon performing it is experienced in both nerve surgery and shoulder endoscopic dissections conducted outside of the glenohumeral joint. In addition, due to extensive scar tissues and shoulder stiffness, BP neurolysis in such post-traumatic indications is rather difficult. Spaces between the conjoint tendon and pectoralis minor and/or between the conjoint tendon and the subscapularis were sometimes difficult to localize because of severe adhesions. In most of the cases, thick scar tissue surrounded the nerves and artery in front of the subscapularis. The greatest risk is to damage the axillary artery or one of its branches, thus resulting in bleeding that may be difficult to control. We would recommend extreme caution while performing the procedure; if any excessive technical difficulty is faced, endoscopy should be stopped and surgery should be resumed in an open fashion. Furthermore, endoscopic neurolysis has been previously used in nerve compression syndromes, such as suprascapular neuropathies and neurogenic thoracic outlet syndromes [20,21,44], as well as in benign tumoral cases [19]. With the absence of any scar tissues and/or perineural adhesions, endoscopic dissection is relatively straightforward in these non-traumatic indications, and may thus be a more adequate option at the beginning of experience.

Finally, the main shortcoming of such endoscopic approach may lie in the very limited possibilities to perform anything else than the dissection itself. If intraneural dissection has been demonstrated feasible and successful [19], to the best of our knowledge, no nerve repair has been performed yet with the use of standard arthroscopic equipment, subsequently precluding suture nerve sutures as well as nerve grafts and/or transfers. With robotic assistance and customized equipment (e.g., needle holder, clamp, scissors forceps...), the feasibility of performing such microsurgical procedures endoscopically has been demonstrated in cadaveric experimentations [45]. However, the relevance of such expensive technology has yet to be proved in clinical practice, since open conversion was required in all patients who underwent robot-assisted BP reconstruction [46,47]. Nonetheless, design of new microsurgical tools, based on those used with the Da Vinci robot but tailored to standard arthroscopic equipment, could be a potential way to further push the technical limits of this technique and subsequently increase its indications.

#### *Limitations of the study*

The main shortcoming of the study relies in the lack of a control group. Considering the rarity of such presentations, unquestionable statistical evidence seems unrealistic to yield in a monocentric study. Furthermore, due to the paucity of the existing literature, no gold-standard approach exists yet to be compared with. In addition, even though no statistical comparison could be made due to smallness of our sample, the complete absence of clinical improvement that we observed in patients who were referred lately, despite several months of conservative treatment in some cases, contrasted with the very satisfactory outcomes that we noted very early after surgical management in the great majority of cases (i.e., 7 patients over 8 who did not need nerve reconstruction). Based on those outcomes, a multicentric prospective comparative trial is currently underway, in order to more precisely assess the potential benefits and limitations of such early surgical management in comparison with traditional conservative treatment. Finally, considering that the data were retrieved from the

pre- and postoperative examinations of the operating surgeon, an observational bias cannot be excluded.

## Conclusions

In the setting of BP palsy due to GHJ dislocation, endoscopic BP neurolysis appears to be a safe and reliable procedure when performed by a shoulder surgeon experienced in peri-articular endoscopic dissection. When performed early, substantial benefits were observed in the great majority of patients at the cost of minimal additional surgical morbidity. Subsequently, we believe that such procedure should be considered as an additional therapeutic option in the management of patients with BP palsy due to GHJ dislocation when no signs of early clinical improvement are observed.

## Institutional review board (IRB) information

Since this study was a retrospective chart review, no formal approval from the IRB of our institution was required. All investigations were conducted in accordance with the 1964 Declaration of Helsinki ethical standards and the MR-003 reference methodology\*; the study was registered in the National Committee for the Computer Sciences and Liberties (Commission Nationale de l'Informatique et des Libertés – CNIL) database register (No. 2217505 v 0) and all patients were individually informed and gave his/her consent before any data collection and/or analysis.

\* Journal Officiel de la République Française n°0189 du 14 août 2016. Texte N°77. <https://www.legifrance.gouv.fr/affichTexte.do?cidTexte=JORFTEXT000033028290&dateTexte=&categorieLien=id>. Access date: 01/01/2020.

## Others

1. The study was conducted at the Alps Surgery Institute – Hand, Upper Limb, Brachial Plexus and Microsurgery Unit (PBMA), Clinique Générale d'Annecy, 4 chemin de la Tour la Reine, 74000 Annecy, France.
2. Malo LE HANNEUR and Manon COLAS equally contributed in the conception of this manuscript.
3. This paper has not been presented to any meetings.

## Source of funding

None.

## Declaration of Competing Interests

The authors declare that they have no conflict of interests. None of them has a financial interest in any of the products, devices, or drugs mentioned in this manuscript. They have not received or will receive any financial aid, in any form, for this study, from any of the following organizations: National Institutes of Health (NIH); Wellcome Trust; Howard Hughes Medical Institute (HHMI); or other(s).

## References

- [1] Shah A, Judge A, Delmestri A, Edwards K, Arden NK, Prieto-Alhambra D, et al. Incidence of shoulder dislocations in the UK, 1995-2015: a population-based cohort study. *BMJ Open* 2017;7:e016112.
- [2] Perron AD, Ingerski MS, Brady WJ, Erling BF, Ullman EA. Acute complications associated with shoulder dislocation at an academic emergency department. *J Emerg Med* 2003;24:141-5.
- [3] Gutkowska O, Martynkiewicz J, Urban M, Gosk J. Brachial plexus injury after shoulder dislocation: a literature review. *Neurosurg Rev* 2018 Epub ahead of print. doi:10.1007/s10143-018-1001-x.
- [4] Gleeson AP. Anterior glenohumeral dislocations: what to do and how to do it. *J Accid Emerg Med* 1998;15:7-12.
- [5] Marsalli M, Sepulveda O, Moran N, Breyer JM. Shoulder terrible triad: classification, functional results, and prognostic factors. *J Am Acad Orthop Surg* 2020;28:200-7.
- [6] Robinson CM, Shur N, Sharpe T, Ray A, Murray IR. Injuries associated with traumatic anterior glenohumeral dislocations. *J Bone Joint Surg Am* 2012;94:18-26.
- [7] Gutkowska O, Martynkiewicz J, Stepniowski M, Gosk J. Analysis of patient-dependent and trauma-dependent risk factors for persistent brachial plexus injury after shoulder dislocation. *Biomed Res Int* 2018;2018:4512137 eCollection 2018. doi:10.1155/2018/4512137.
- [8] Liveson JA. Nerve lesions associated with shoulder dislocation; an electrodiagnostic study of 11 cases. *J Neurol Neurosurg Psychiatry* 1984;47:742-4.
- [9] Visser CP, Tavy DL, Coene LN, Brand R. Electromyographic findings in shoulder dislocations and fractures of the proximal humerus: comparison with clinical neurological examination. *Clin Neurol Neurosurg* 1999;101:86-91.
- [10] Fox M, Lambert S, Birch R. The terrible triad of the shoulder. *Bone Joint J* 2009;91-B(Suppl 1):13-20.
- [11] Hems TE, Mahmood F. Injuries of the terminal branches of the infraclavicular brachial plexus: patterns of injury, management and outcome. *J Bone Joint Surg Br* 2012;94:799-804.
- [12] Atef A, El-Tantawy A, Gad H, Hefeda M. Prevalence of associated injuries after anterior shoulder dislocation: a prospective study. *Int Orthop* 2016;40:519-24.
- [13] Sunderland S. Nerves and nerve injuries. Edinburgh: Churchill Livingstone; 1978.
- [14] Seddon H. Three types of nerve injury. *Brain* 1943;66:238-83.
- [15] Burge P, Rushworth G, Watson N. Patterns of injury to the terminal branches of the brachial plexus. The place for early exploration. *J Bone Joint Surg Br* 1985;67:630-4.
- [16] Kosiyaatrakul A, Jitprapaikularn S, Durand S, Oberlin C. Recovery of brachial plexus injury after shoulder dislocation. *Injury* 2009;40:1327-9.
- [17] Dhar D. Anterior dislocation of shoulder with brachial plexus injury. *J Coll Physicians Surg Pak* 2007;17:110-11.
- [18] Lafosse T, Masmejean E, Bihel T, Lafosse L. Brachial plexus endoscopic dissection and correlation with open dissection. *Chir Main* 2015;34:286-93.
- [19] Lafosse T, Le Hanneur M, Popescu IA, Bihel T, Masmejean E, Lafosse L. 20. All-Endoscopic resection of an infraclavicular brachial plexus schwannoma: surgical technique. *Arthrosc Tech* 2018;7:e869-73.
- [20] Lafosse T, Le Hanneur M, Lafosse L. All-endoscopic brachial plexus complete neurolysis for idiopathic neurogenic thoracic outlet syndrome: surgical technique. *Arthrosc Tech* 2017;6(4):e967-71.
- [21] Lafosse T, Le Hanneur M, Lafosse L. All-endoscopic brachial plexus complete neurolysis for idiopathic neurogenic thoracic outlet syndrome: a prospective case series. *Arthroscopy* 2017;33:1449-57.
- [22] Niver GE, Ilyas AM. Management of radial nerve palsy following fractures of the humerus. *Orthop Clin North Am* 2013;44:419-24.
- [23] Keighley G, Hermans D, Lawton V, Duckworth D. Radial nerve palsy in mid/distal humeral fractures: is early exploration effective. *ANZ J Surg* 2018;88:228-31.
- [24] Rasulic L, Savic A, Vitosevic F, Samardzic M, Zivkovic B, Micovic M, et al. Iatrogenic peripheral nerve injuries-surgical treatment and outcome: 10 years' experience. *World Neurosurg* 2017;103:841-51.
- [25] Journal Officiel de la République Française n°0189 du 14 août 2016. Texte N°77. <https://www.legifrance.gouv.fr/affichTexte.do?cidTexte=JORFTEXT000033028290&dateTexte=&categorieLien=id>.
- [26] Lafosse T, Gerosa T, Seran J, Bouyer M, Masmejean EH, Le Hanneur M. Double-nerve transfer to the axillary nerve in traumatic upper trunk brachial plexus injuries using an axillary approach: anatomical description and preliminary case series. *Oper Neurosurg (Hagerstown)* 2020 Epub ahead of print. doi:10.1093/ons/ozp430.
- [27] Takase F, Inui A, Mifune Y, Muto T, Harada Y, Kokubu T, et al. Concurrent rotator cuff tear and axillary nerve palsy associated with anterior dislocation of the shoulder and large glenoid rim fracture: a "terrible tetrad". *Case Rep Orthop* 2014;2014:312968.
- [28] de Laat EA, Visser CP, Coene LN, Pahlplatz PV, Tavy DL. Nerve lesions in primary shoulder dislocations and humeral neck fractures. A prospective clinical and EMG study. *J Bone Joint Surg Br* 1994;76:381-3.
- [29] Midha R. Epidemiology of brachial plexus injuries in a multitrauma population. *Neurosurgery* 1997;40:1182-9.
- [30] Rathore S, Kasha S, Yeggana S. Fracture dislocation of shoulder with brachial plexus palsy: a case report and review of management options. *J Orthop Case Rep* 2017;7:48-51.
- [31] Stenning M, Drew S, Birch R. Low-energy arterial injury at the shoulder with progressive or delayed nerve palsy. *J Bone Joint Surg Br* 2005;87:1102-6.
- [32] Saragaglia D, Picard F, Le Bredonchel T, Moncenis C, Sardo M, Tourne Y. [Acute anterior instability of the shoulder: short- and mid-term outcome after conservative treatment]. [Article in French]. *Rev Chir Orthop Reparatrice Appar Mot* 2001;87:215-20.
- [33] Travlos J, Goldberg I, Boome RS. Brachial plexus lesions associated with dislocated shoulders. *J Bone Joint Surg Br* 1990;72:68-71.
- [34] Leffert RD, Seddon H. Infraclavicular brachial plexus injuries. *J Bone Joint Surg Br* 1965;47:9-22.
- [35] Kline DG. Timing for brachial plexus injury: a personal experience. *Neurosurg Clin N Am* 2009;20:24-6.
- [36] Wehbe J, Maalouf G, Habanbo J, Chidiac RM, Braun E, Merle M. Surgical treatment of traumatic lesions of the axillary nerve. A retrospective study of 33 cases. *Acta Orthop Belg* 2004;70:11-18.



- [37] Kandenwein JA, Kretschmer T, Engelhardt M, Richter HP, Antoniadis G. Surgical interventions for traumatic lesions of the brachial plexus: a retrospective study of 134 cases. *J Neurosurg* 2005;103:614–21.
- [38] Giuffre JL, Kakar S, Bishop AT, Spinner RJ, Shin AY. Current concepts of the treatment of adult brachial plexus injuries. *J Hand Surg Am* 2010;35:678–88.
- [39] Limthongthang R, Bachoura A, Songcharoen P, Osterman AL. Adult brachial plexus injury: evaluation and management. *Orthop Clin North Am* 2013;44:591–603.
- [40] Battiston B, Vasario G, Marccocio I, Titolo P. Traumatic brachial plexus injuries. In: Peretti G, editor. *Neurologic shoulder*. Bologna: TIMEO Editore; 2015. p. 57–65.
- [41] Birch R. *Surgical disorders of the peripheral nerves*. London: Springer; 2011.
- [42] Kobayashi J, Mackinnon SE, Watanabe O, Ball DJ, Gu XM, Hunter DA, et al. The effect of duration of muscle denervation on functional recovery in the rat model. *Muscle Nerve* 1997;20:858–66.
- [43] Brown BA. Internal neurolysis in treatment of traumatic peripheral nerve lesions. *Calif Med* 1969;110:460–2.
- [44] Lafosse L, Tomasi A, Corbett S, Baier G, Willems K, Gobezie R. Arthroscopic release of suprascapular nerve entrapment at the suprascapular notch: technique and preliminary results. *Arthroscopy* 2007;23:34–42.
- [45] Mantovani G, Liverneaux P, Jr Garcia JC, Berner SH, Bednar MS, Mohr CJ. Endoscopic exploration and repair of brachial plexus with telerobotic manipulation: a cadaver trial. *J Neurosurg* 2011;115:659–64.
- [46] Jr Garcia JC, F Lebailly, Mantovani G, Mendonca LA, Garcia J, Liverneaux P. Telerobotic manipulation of the brachial plexus. *J Reconstr Microsurg* 2012;28:491–4.
- [47] Facca S, Hendriks S, Mantovani G, Selber JC, Liverneaux P. Robot-assisted surgery of the shoulder girdle and brachial plexus. *Semin Plast Surg* 2014;28:39–44.