



Available online at  
**ScienceDirect**  
www.sciencedirect.com

Elsevier Masson France  
**EM|consulte**  
www.em-consulte.com/en



Original article

# Triple-bundle anatomical reconstruction using the coracoacromial ligament and the short head of biceps tendon to stabilize chronic acromioclavicular joint dislocations: A cadaver feasibility study

M. Le Hanneur<sup>a,b,\*</sup>, D. Delgrande<sup>c</sup>, T. Lafosse<sup>b</sup>, J.-D. Werthel<sup>c</sup>, P. Hardy<sup>c</sup>, B. Elhassan<sup>a</sup>

<sup>a</sup> Department of Orthopedic Surgery, Mayo Clinic, 200 First Street SW, Rochester, MN 55905, USA

<sup>b</sup> Department of Orthopedics and Traumatology, Service of Hand, Upper Limb and Peripheral Nerve Surgery, Georges-Pompidou European Hospital (HEGP), Assistance publique-Hôpitaux de Paris (AP-HP), 20, rue Leblanc, 75015 Paris, France

<sup>c</sup> Department of Orthopedics and Traumatology, Ambroise-Paré Hospital, Assistance publique-Hôpitaux de Paris (AP-HP), 9, avenue Charles-de-Gaulle, 92100 Boulogne, France

## ARTICLE INFO

### Article history:

Received 27 March 2017  
Accepted 7 November 2017

### Keywords:

Acromioclavicular joint  
Coracoclavicular ligament  
Coracoacromial ligament  
Conjoined tendon  
Anatomical reconstruction

## ABSTRACT

**Introduction:** In cases of chronic acromioclavicular joint separation, the biomechanical properties of anatomical reconstructions are closer to the native configuration than the Weaver–Dunn procedure. Consequently, the radiological and clinical outcomes are better. However, an additional incision is needed to harvest the graft, which increases the procedure's morbidity.

**Hypothesis:** Triple-bundle reconstruction can be performed with the coracoacromial ligament (CAL) and the semi conjoined tendon (SCT).

**Material and methods:** Bilateral dissection was performed on the upper limb of six fresh-frozen cadavers. Measurements useful to the procedure were taken on one limb, specifically the minimum graft length needed and the available length. The surgical procedure was performed on the other limb. The proximally based SCT was passed through the base of the coracoid process, then divided into two strips tightened from the superior aspect of the coracoid process to the clavicular insertion points of the conoid and trapezoid ligaments. The CAL was detached from the coracoid process and then secured in the medullary canal of the clavicle, after its lateral one-quarter was resected (i.e., 10 mm).

**Results:** The mean length of the SCT was  $101.7 \pm 7.6$  mm (95.1–114.5) and the mean length of the CAL was  $35.3 \pm 4.7$  mm (28.7–42.5). The SCT length needed for this reconstruction was  $58 \pm 4.3$  mm (51.5–62) medially and  $60.3 \pm 4.6$  mm (54.3–66.3) laterally. The procedure was feasible in all six cadavers with an average excess length of  $39.9 \pm 5.7$  mm (32.2–47) for the conoid bundle,  $37.6 \pm 5$  mm (31–45.1) for the trapezoid ligament and  $6 \pm 2.7$  mm (3–9.5) for the CAL.

**Discussion:** Triple-bundle anatomical reconstruction using the SCT and CAL is feasible. However, the strength of this construct must be evaluated biomechanically before it can be used clinically.

**Level of evidence:** Not applicable – cadaver study.

© 2017 Elsevier Masson SAS. All rights reserved.

## 1. Introduction

Along with dynamic contributions of the deltoid muscle anteriorly and the trapezius muscle posteriorly, stability of the acromioclavicular (AC) joint depends on three main ligament

structures: the AC ligaments (considered as one functional unit) and the two coracoclavicular (CC) ligaments, including the conoid ligament medially and the trapezoid ligament laterally [1]. Given the anatomical position of this joint, acute AC joint separations are relatively common, representing 3.2% of all shoulder girdle injuries. They usually occur following a direct impact on the shoulder during high-energy falls [2]. On the other hand, the development of chronic instability is rare due to the availability of effective surgical techniques that stabilize high-grade acute tears and the overall effectiveness of conservative treatment for low-grade tears [3]. Nevertheless, simple stabilization is not sufficient in cases of chronic instability given that the healing potential of ligaments

\* Corresponding author at: Department of Orthopedics and Traumatology, Service of Hand, Upper Limb and Peripheral Nerve Surgery, Georges-Pompidou European Hospital (HEGP), Assistance publique-Hôpitaux de Paris (AP-HP), 20, rue Leblanc, 75015 Paris, France.  
E-mail address: malo.lehanneur@gmail.com (M. Le Hanneur).

decreases over time [4]. For this reason, the Francophone Society of Arthroscopy recommends adding a biological graft if the injury is more than 10 days old [5].

Historically, acromioclavicular ligament reconstruction involved local grafts that were pedicled to the coracoid process anteriorly and secured to the clavicle posteriorly. In 1942, Vargas proposed using either the lateral part of the conjoined tendon (i.e., semi conjoined tendon – SCT) or the short head of biceps tendon [6]. Thirty years later, Weaver and Dunn described a reconstruction procedure using the coracoacromial ligament (CAL) [7]. Despite the popularity of these reconstruction methods, they do not reproduce the anatomy of the native triple-bundle ligament complex. Their biomechanical properties were found to be less than those of the native joint, leading to unpredictable radiological and clinical outcomes [8–10].

More recently, anatomical reconstruction techniques have been proposed to restore the native ligament configuration and its various bundles more faithfully. Consequently, their biomechanical properties are close to that of the native joint, and the clinical and radiological outcomes appears to be better [11–13]. The drawback of these procedures is that the grafts are harvested from a separate surgical site, increasing the morbidity [14].

The aims of this cadaver study were:

- to assess the feasibility of triple-bundle reconstruction using local grafts (i.e., SCT and CAL);
- to describe the anatomical features needed to carry out the procedure.

## 2. Material and methods

### 2.1. Study population

Bilateral dissection was performed on the upper limb of six fresh-frozen cadavers (2 male, 4 female) thawed for 24 hours at room temperature. Medical records of the donors were reviewed to ensure they had no history of acromioclavicular joint injury or surgery. In addition, radiographs were taken of the AC joints bilaterally before the dissection was initiated. Measurements useful to the procedure were taken on one limb, specially the minimum graft length needed and the available length. The procedure was performed on the other limb. The side was chosen randomly.

### 2.2. Cadaver study

After a large anteroposterior skin incision was made over the shoulder, the trapezius and deltoid muscles were detached from the clavicle and scapula. Next, the pectoralis major and minor muscles were detached from the humerus and coracoid process, respectively, to expose the conjoined tendon. The proximal portion of the conjoined tendon was left intact. The distal portion was transected at the musculotendinous junction, then, separated from the muscle belly using a scalpel. It was then divided longitudinally over its entire length, to end up with a 12-mm wide lateral strip [15]. The musculocutaneous nerve was identified and its distance from the tip of the coracoid process was recorded. The subscapularis, supraspinatus and infraspinatus muscles were then detached distally and reflected proximally to allow the glenohumeral joint to be disarticulated. Lastly, the clavicle was transected laterally to the pectoralis major insertion, and the scapula horizontally under the glenoid, and in a parasagittal plane medial to the neck, in order to remove the acromion and lateral portion of the scapular spine. Once the scapuloacromial unit was isolated, various bone, ligament and tendon structures were measured using a slide caliper with 0.1 mm accuracy (Mitutoyo, Kawasaki, Japan). The grafts were measured

first, specifically the length of the SCT (labeled L) and the anterior width and lateral length of the CAL (labeled I). The CC ligaments were measured next:

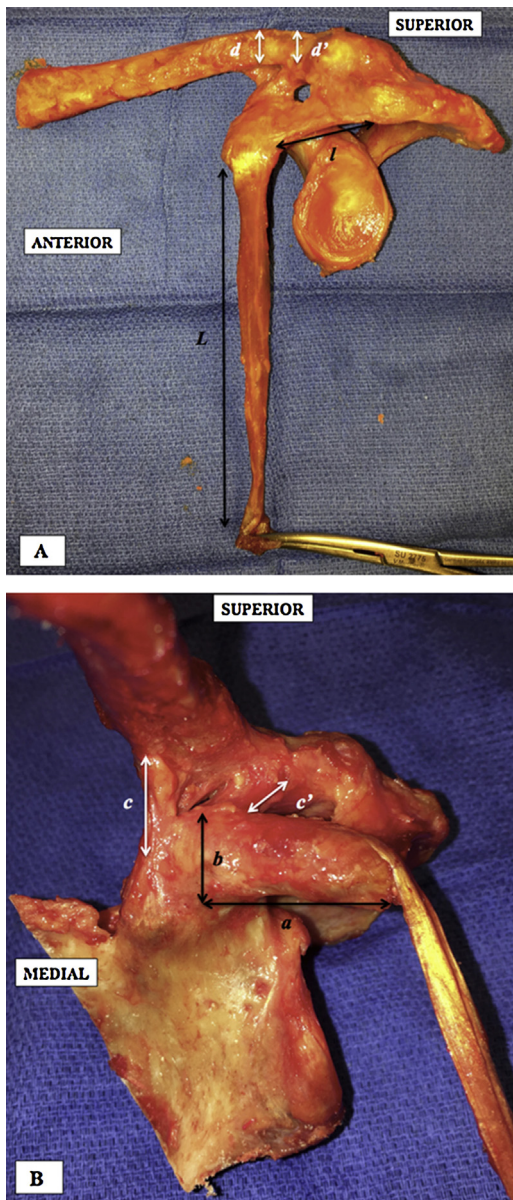
- length at medial edge for conoid ligament and anterior edge for trapezoid ligament (labeled c and c', respectively);
- distance between tip of coracoid process and anterior edge of their coracoid insertion (labeled, CORc and CORt, respectively);
- distance between acromioclavicular joint line and the middle of their clavicular insertion (labeled AACc and AACt, respectively).

The bone elements were measured next. The length of the coracoid process was measured from its tip to the precipice, defined by Salzman et al. as the point where the horizontal direction of the underside of the coracoid process becomes vertical [16]. Its medial to lateral width and its superior to inferior thickness (labeled b) were measured at its base [17]. The clavicle dimensions were taken over the conoid and trapezoid ligament insertions, along with the anterior–posterior width and superior–inferior thickness (labeled d for the conoid and d' for the trapezoid). Once these measurements had been taken, the distances D and D' were calculated, such that  $D = a + b + c + d$  and  $D' = a + b + c' + d'$ . These values reflected the minimum graft length needed to carry out anatomical reconstruction of the conoid and trapezoid ligaments, respectively, with the SCT pedicled proximally onto the coracoid process (Fig. 1A and B).

### 2.3. Surgical technique

The specimen was placed supine with a block between the shoulders and the arm along the body. A deltopectoral approach was used to expose the coracoid process and the conjoined tendon. Once isolated, the conjoined tendon was divided longitudinally, and a 12-mm wide lateral strip was raised with a scalpel in an anterograde manner by progressively flexing the elbow to prevent excessive traction onto the musculocutaneous nerve [15]. The length of the harvested strip was measured. The musculocutaneous nerve was identified where it enters the coracobrachialis muscle and it was reflected backwards with the muscle body when the tendon was elevated. The SCT was then divided into two 6-mm wide strips. Each was reinforced with a Krackow suture using Ethibond® #2 (Ethicon, Somerville, NJ, USA) and then preserved in a humid compress (Fig. 2) [18,19]. A second incision was made on top of the distal clavicle and curved forwards and outwards, in order to access the CAL without placing tension on the skin. The deltoid and trapezius muscles were detached subperiosteally from clavicle. A Rockwood type III injury was then simulated by transecting the AC and CC ligaments (Fig. 3) [20]. Once the two SCT strips were retrieved through the second incision, the CAL was detached from the coracoid process and reinforced with a Krackow suture using Ethibond® #5 [15].

The clavicle was then prepared for the reconstruction. A 4-mm wide hole was drilled 35 mm from the AC joint and centered on the superior surface of the clavicle in the anteroposterior direction. This hole was extended to the base of the coracoid process, until it pierced it in the middle. A second hole was drilled 25 mm from the AC joint through the clavicle only [17]. Lastly, the distal 5–10 mm of the clavicle was resected [21], allowing two 1-mm tunnels to be drilled using K-wires. These were started 10 mm inside the resection margin on the superior clavicular surface and ended in the cut edge, 10 mm apart in the sagittal plane. The acromioclavicular defect created by resecting the AC joint and the distal tip of the clavicle was measured from the midline portion of the clavicular cut to the posterior portion of the CAL's acromial insertion. The reconstruction was then finalized. The two SCT strips were passed below the coracoid process. After crossing its base, the two strips were separated into their individual clavicular tunnels. After the joint

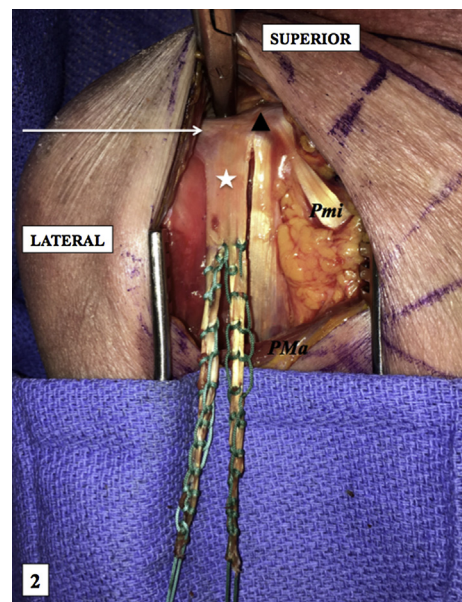


**Fig. 1.** Anterior (A) and medial (B) views of a left scapuloacromioclavicular block after dissection. The length of the coracoacromial ligament and lateral half of the conjoint tendon (*l* and *L*, respectively), as well as minimal length needed to reconstruct the conoid ( $a + b + c + d$ ) and trapezoid ( $a + b + c' + d'$ ) ligaments were measured. The measurement technique is described in the Material and Methods–Anatomical study section.

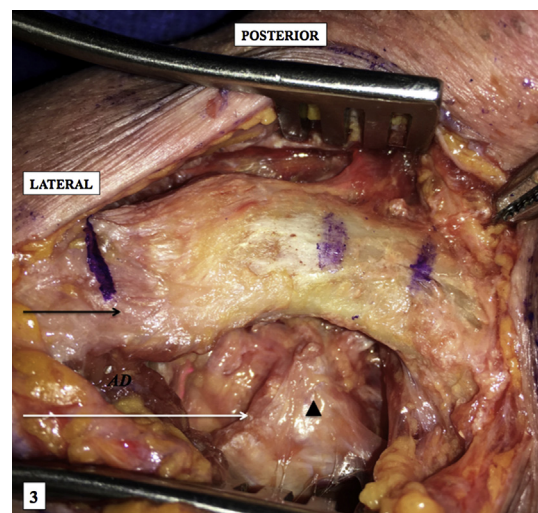
was reduced, the excess length of each strip was measured, and then the two strips were secured to each other (Fig. 4A and B). The future intraosseous portion of the CAL was measured while placed anteriorly to the anterior cortex of the distal clavicle, in position for reduction. It was then tunneled intramedullary. The two ends of the Krackow sutures were placed through the K-wire tunnels and tied together on its superior surface (Fig. 5).

#### 2.4. Statistical analysis

Since the continuous quantitative variables were not normally distributed according to the Shapiro–Wilk test, they were analyzed using the Wilcoxon signed rank test. The significance threshold was set at  $p < 0.05$  for all statistical tests. The results are described by the mean  $\pm$  standard deviation (range), except when specified. SPSS



**Fig. 2.** Deltopectoral approach used to harvest and prepare the lateral half of the conjoint tendon (white star) in a right shoulder. Seen attached to the coracoid (black triangle) are the coracoacromial ligament laterally (white arrow) and the pectoralis minor muscle medially (Pmi). Note the harvested band is longer than the incision, which is made possible by anterior retraction of the pectoralis major muscle (PMa) and elbow flexion.



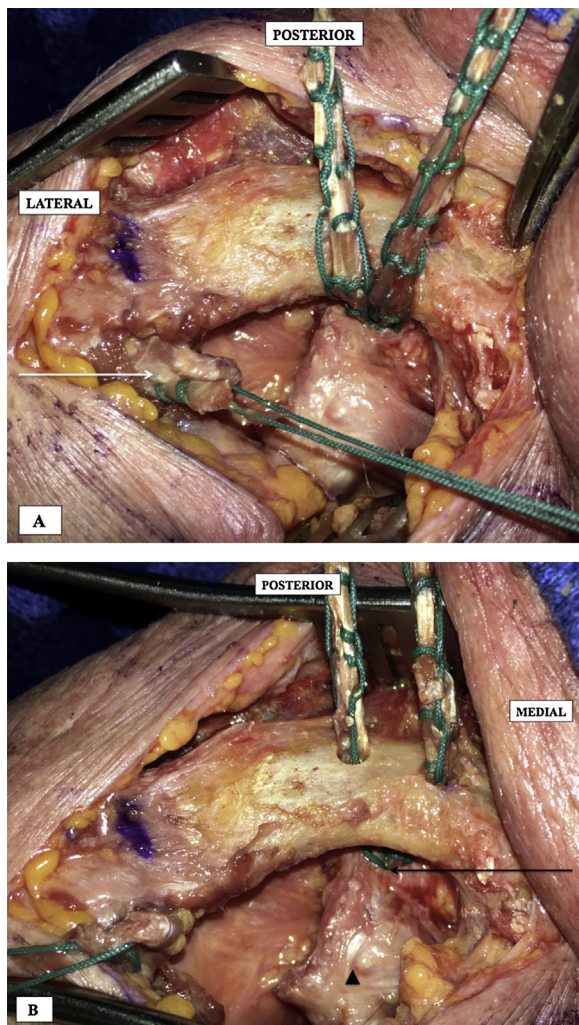
**Fig. 3.** Superior longitudinal approach used to detach the anterior deltoid (AD) proximally in a right shoulder. This exposes the acromioclavicular joint, along with the superior aspect of the coracoid process (black triangle), from which the coracoacromial ligament was previously detached (white arrow). Note the future position of the clavicular tunnels, 25 and 35 mm medial to the acromioclavicular joint.

software (version 22.0, IBM, Armonk, NY, USA) was used to carry out the calculations.

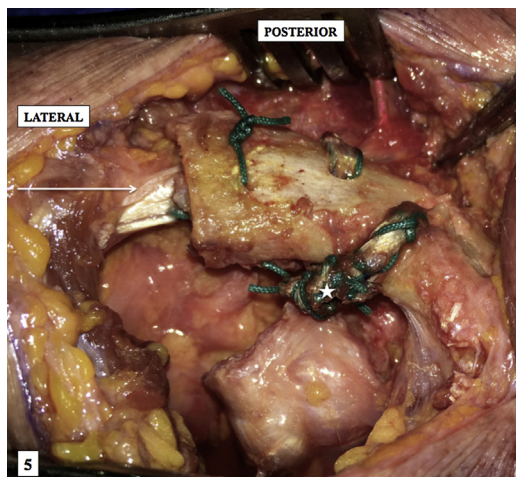
### 3. Results

#### 3.1. Anatomical characteristics

The length *L* of the SCT was  $101.7 \pm 7.6$  mm (95.1–114.5) and was statistically longer than the two distances *D* and *D'* in every specimen ( $p = 0.03$ ) (Table 1). The musculoskeletal nerve was found in every specimen in the muscle belly of the short head of biceps at an average distance of  $44.3 \pm 8.1$  mm (32.3–55.5) from the tip of the coracoid process. The length *l* of the CAL (lateral margin) was



**Fig. 4.** Superior view of the right acromioclavicular joint, showing the lateral half of the conjoint tendon passing through the coracoid process base first (A) and then through the clavicle (B). The coracoacromial ligament has been detached from the coracoid and prepared with a Krackow suture (white arrow).



**Fig. 5.** Superior view of the completed reconstruction, with the coracoacromial ligament pulled into the medullary canal of the clavicle (white arrow), along with the two coracoclavicular bands tied together anteriorly (white star); this avoids having bulky tissue on the superior side of the clavicle.

**Table 1**  
Anatomical characteristics<sup>a</sup>.

	Mean	Standard deviation (SD)	Range
<b>CC ligament reconstruction</b>			
Coracoid process			
Length – a	20.0	3.5	16.9–26.3
Width	23.0	3.0	19.9–28.2
Height – b	13.5	1.9	11.2–16.3
Conoid ligament			
Length – c	18.5	1.8	16–21.1
Distance CORc	35.1	2.9	31.1–38.6
Distance AACc	32.4	2.2	29.8–35.2
Trapezoid ligament			
Length – c'	17.5	1.3	15.3–19.3
Distance CORt	28.7	2.5	25–31.1
Distance AACt	23.4	2.6	19.9–25.8
Clavicle			
Medial height – d	10.3	0.7	9.4–11.4
Medial width	24.0	2.2	21–27.2
Lateral height – d'	10.5	1.0	9–11.4
Lateral width	25.1	2.7	21.2–27.5
D = a + b + c + d	62.3	7.2	55.3–75.1
D' = a + b + c' + d'	61.5	6.0	56–71.3
<b>AC ligament reconstruction</b>			
Coracoacromial ligament (CAL)			
Length	35.3	4.7	28.7–42.5
Width	26.6	2.9	22.8–31.7
AC defect after resection	17.3	1.9	14.9–19.5
Length of CAL in tunnel after transfer	6.0	2.7	3–9.5

The various measurements are described in detail in the [Materials and methods section](#) of this article.

CC: coracoclavicular; AC: acromioclavicular.

<sup>a</sup> All values in mm.

$35.3 \pm 4.7$  mm (28.7–42.5), for a width of  $26.6 \pm 2.9$  mm (22.8–31.7) at its coracoid insertion. There were no distinctive anatomical features in the muscle, tendon, bone and ligament structures.

### 3.2. Surgical technique

Triple-bundle reconstruction was feasible on every specimen. The length of the harvested SCT was  $97.9 \pm 6.1$  mm (90–105.7). While this was significantly less than the available length L measured on the contralateral shoulder ( $p=0.031$ ), the two strips always had excess length:  $39.9 \pm 5.7$  mm (32.2–47) for the medial one and  $37.6 \pm 5$  mm (31–45.1) for the lateral one. If these values are subtracted from the initial length of the harvested SCT, the length of the reconstructed coracoclavicular bundles was  $58.0 \pm 4.3$  mm (51.5–62) medially and  $60.3 \pm 4.6$  mm (54.3–66.3) laterally. There was no significant difference between these “true” values and contralateral “theoretical” values D and D' ( $p=0.31$  and  $p=0.69$ , respectively).

After the distal tip of the clavicle was resected, the AC defect averaged  $17.3 \pm 1.9$  mm (14.9–19.5). Like the CC reconstruction, the CAL had excess length in all specimens. This allowed its anterior end to be inserted into the clavicle’s medullary canal. The interosseous portion of the CAL was  $6.0 \pm 2.7$  mm (3–9.5) long on average.

## 4. Discussion

This study demonstrates the feasibility of triple-bundle anatomical reconstruction of the stabilizing ligament complex of the acromioclavicular joint using only pedicled local grafts—the coracoacromial ligament and semi conjoint tendon.

### 4.1. Déjà-vu and novelty

The advantage of these grafts is that they have been used for many years in this type of surgery. Hence, several of their charac-

teristics are known, particularly their anatomy and associated risks, such as the acromial branch of the acromiothoracic artery running along the superior surface of the CAL requiring hemostasis [22]. Also, the musculocutaneous nerve, which penetrates the coracobrachialis muscle 3 to 5 cm below the tip of the coracoid process, must be preserved [19]. Morbidity secondary to harvesting these grafts has been analyzed biomechanically and clinically. There was no evidence of a contraindication to complete harvesting of the CAL, except in cases of massive rotator cuff tear, with the latter preventing anterosuperior instability [23]. Lastly, since their ability to withstand traction is less than that of the CC ligaments, they must be reinforced using a strong braided suture [15,19,24].

Conversely, their use for anatomical aims is very limited. Kim et al. reported on double-bundle reconstruction using the CAL for the trapezoid ligament and the SCT for the conoid ligament [25]. Since the grafts were tightened directly from their coracoid origin to their new clavicular insertion, the anatomy of the CC ligaments was not truly restored. In our study, the angle imposed on the SCT by the transcoracoid tunnel made it possible to reproduce the course of the conoid and trapezoid ligaments, from the base of the coracoid process to their clavicular insertion points. Since the latter are  $35.0 \pm 5.9$  mm and  $25.9 \pm 3.9$  mm from the AC joint, respectively, in the Rios et al. study [17] and in our study, the clavicular tunnels must be positioned accordingly. The drawback of this less-direct course is that a longer graft is needed. We have shown that although the length of SCT harvested is significantly less than the available length, it was still long enough in every case.

#### 4.2. Biomechanical rationale

The triple-bundle ligament complex must be restored for the AC joint to be stable in the vertical and horizontal planes. Fukuda et al. have shown how important the AC ligaments are for withstanding small displacements and also for large posterior displacements [26]. Hence, the CAL tensioned from its acromial insertion appears to be a satisfactory option for a third bundle, in order to prevent horizontal instability [27]. Conversely, the conoid and trapezoid ligaments combat vertical instability and axial compression, respectively, as they mainly act to prevent large superior displacements and axial compression. For this reason, their course must start at the base of the coracoid process, not its tip, so as to reduce their arc of rotation as much as possible [19,25]. The fracture risk induced by a single transcoracoid tunnel has been shown to be nonexistent, if the tunnel is centered [11].

This study has the same limitations as any cadaver feasibility study, particularly the lack of biomechanical validation. The biomechanical advantages of this triple-bundle reconstruction are purely theoretical and must be validated in another study. Moreover, the procedure described here requires sizeable approaches, with detachment of the anterior deltoid potentially negatively impacting the clinical outcomes. Endoscopic harvesting of the SCT and CAL should be considered to reduce this risk [28].

#### 5. Conclusion

This study demonstrates the feasibility of triple-bundle reconstruction with the SCT and CAL, and describes the anatomical characteristics required to complete it.

#### Funding

The first author received an institutional Master's degree scholarship of €22,000 from the SOFCOT (French Society of Orthopedic Surgery and Traumatology) that provided financial support for his 1-year research fellowship at the Mayo Clinic.

#### Disclosure of interest

M. Le Hanneur received an institutional grant from the French Orthopedic Society (SOFCOT) to complete his research fellowship at Mayo Clinic. P. Hardy is occasional consultant for Athrex and Zimmer. The other authors declare that they have no competing interest.

#### Acknowledgements

The first author is grateful to the SOFCOT (French Society of Orthopedic Surgery and Traumatology) for granting him a Master's degree scholarship that allowed him to visit the Mayo Clinic in the USA as a Research Fellow where he carried out this study.

#### References

- [1] Epstein D, Day M, Rokito A. Current concepts in the surgical management of acromioclavicular joint injuries. *Bull Hosp Jt Dis* 2012;70:11–24.
- [2] Beitzel K, Cote MP, Apostolakis J, et al. Current concepts in the treatment of acromioclavicular joint dislocations. *Arthroscopy* 2013;29:387–97.
- [3] Tauber M. Management of acute acromioclavicular joint dislocations: current concepts. *Arch Orthop Trauma Surg* 2013;133:985–95.
- [4] Lee DH, Ng J, Chung JW, Sonn CH, Lee KM, Han SB. Impact of chronicity of injury on the proportion of mesenchymal stromal cells derived from anterior cruciate ligaments. *Cytotherapy* 2014;16:586–98.
- [5] Barth J, Duparc F, Andrieu K, French Society of Arthroscopy, et al. Is coracoclavicular stabilisation alone sufficient for the endoscopic treatment of severe acromioclavicular joint dislocation (Rockwood types III, IV, and V)? *Orthop Traumatol Surg Res* 2015;101:S297–303.
- [6] Vargas L. Repair of complete acromioclavicular dislocation, utilizing the short head of the biceps. *J Bone Joint Surg Am* 1942;24:772–3.
- [7] Weaver JK, Dunn HK. Treatment of acromioclavicular injuries, especially complete acromioclavicular separation. *J Bone Joint Surg Am* 1972;54:1187–94.
- [8] Deshmukh AV, Wilson DR, Zilberfarb JL, Perlmutter GS. Stability of acromioclavicular joint reconstruction: biomechanical testing of various surgical techniques in a cadaveric model. *Am J Sports Med* 2004;32:1492–8.
- [9] Weinstein DM, McCann PD, McIllyen SJ, Flatow EL, Bigliani LU. Surgical treatment of complete acromioclavicular dislocations. *Am J Sports Med* 1995;23:324–31.
- [10] Tienen TG, Oyen JF, Eggen PJ. A modified technique of reconstruction for complete acromioclavicular dislocation: a prospective study. *Am J Sports Med* 2003;31:655–9.
- [11] Mazzocca AD, Santangelo SA, Johnson ST, Rios CG, Dumonski ML, Arciero RA. A biomechanical evaluation of an anatomical coracoclavicular ligament reconstruction. *Am J Sports Med* 2006;34:236–46.
- [12] Michlitsch MG, Adamson GJ, Pink M, Estess A, Shankwiler JA, Lee TQ. Biomechanical comparison of a modified Weaver-Dunn and a free-tissue graft reconstruction of the acromioclavicular joint complex. *Am J Sports Med* 2010;38:1196–203.
- [13] Tauber M, Valler D, Lichtenberg S, Magosch P, Moroder P, Habermeyer P. Arthroscopic stabilization of chronic acromioclavicular joint dislocations: triple-versus single-bundle reconstruction. *Am J Sports Med* 2016;44:482–9.
- [14] Lee SJ, Nicholas SJ, Akizuki KH, McHugh MP, Kremenic IJ, Ben-Avi S. Reconstruction of the coracoclavicular ligaments with tendon grafts: a comparative biomechanical study. *Am J Sports Med* 2003;31:648–55.
- [15] Sloan SM, Budoff JE, Hipp JA, Nguyen L. Coracoclavicular ligament reconstruction using the lateral half of the conjoined tendon. *J Shoulder Elbow Surg* 2004;13:186–90.
- [16] Salzmann GM, Paul J, Sandmann GH, Imhoff AB, Schöttle PB. The coracoid insertion of the coracoclavicular ligaments: an anatomic study. *Am J Sports Med* 2008;36:2392–7.
- [17] Rios CG, Arciero RA, Mazzocca AD. Anatomy of the clavicle and coracoid process for reconstruction of the coracoclavicular ligaments. *Am J Sports Med* 2007;35:811–7.
- [18] Krackow KA. The Krackow suture: how, when, and why. *Orthopedics* 2008;31:931–3.
- [19] Jiang C, Wang M, Rong G. Proximally based conjoined tendon transfer for coracoclavicular reconstruction in the treatment of acromioclavicular dislocation. *J Bone Joint Surg Am* 2007;89:2408–12.
- [20] Rockwood CA. Injuries to the acromioclavicular joint. In: Rockwood CA, Green DP, editors. *Fractures in adults*, Volume 1, 2nd ed. Philadelphia: JB Lippincott; 1984. p. 860–910.
- [21] Branch TP, Burdette HL, Shahriari AS, Carter 2nd FM, Hutton WC. The role of the acromioclavicular ligaments and the effect of distal clavicle resection. *Am J Sports Med* 1996;24:293–7.
- [22] Lafosse L, Baier GP, Leuzinger J. Arthroscopic treatment of acute and chronic acromioclavicular joint dislocation. *Arthroscopy* 2005;21:1017.
- [23] Wiley AM. Superior humeral dislocation. A complication following decompression and debridement for rotator cuff tears. *Clin Orthop Relat Res* 1991;263:135–41.

- [24] Najibi S, Banglmeier R, Matta J, Tannast M. Material properties of common suture materials in orthopaedic surgery. *Iowa Orthop J* 2010;30:84–8.
- [25] Kim SH, Lee YH, Shin SH, Lee YH, Baek GH. Outcome of conjoined tendon and coracoacromial ligament transfer for the treatment of chronic type V acromioclavicular joint separation. *Injury* 2012;43:213–8.
- [26] Fukuda K, Craig EV, An KN, Cofield RH, Chao EY. Biomechanical study of the ligamentous system of the acromioclavicular joint. *J Bone Joint Surg Am* 1986;68:434–40.
- [27] Saier T, Venjakob AJ, Minzlaff P, Föhr P, Lindell F, Imhoff AB, et al. Value of additional acromioclavicular cerclage for horizontal stability in complete acromioclavicular separation: a biomechanical study. *Knee Surg Sports Traumatol Arthrosc* 2015;23:1498–505.
- [28] Kany J, Guinand R, Croutzet P. All arthroscopic augmented Vargas procedure: an option after failed acromioclavicular joint dislocation reconstruction. A technical note. *Orthop Traumatol Surg Res* 2016;102:669–72.